

Dear A Life A Time donors,

We want to thank you for your continued support in our efforts in helping orphaned and impoverished children in China who suffer from congenital illnesses or severe trauma. During the past three months, with the money from our many generous donors on both our A Life A Time and GlobalGiving websites, we were able to provide assistance to a total of 13 children and one foster home in China!

Below is a summary of some individual children who we helped between June 2015 and August 2015. For detailed information on all the children we have helped and those who are still in need of your help, please visit our website: <http://www.alifetime.org>

For additional information on the uses of the donations we have received via the GlobalGiving platform, please visit the following link: http://www.alifetime.org/cn/help/donation_list.aspx?id=761

Demao

Gender: Male

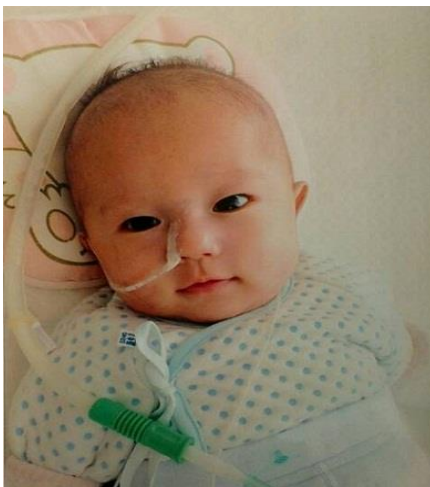
Disease/Illness: Congenital Esophageal Atresia

Date of Birth: August 2013

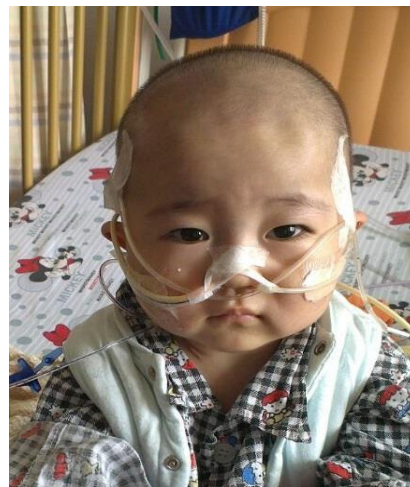Contribution from A Life A Time: \$3,735.72

Story link: <http://www.alifetime.org/cn/children/story.aspx?id=730>

Only a few hours after he was born, Demao was diagnosed with congenital esophageal atresia, which is the failure of the esophagus to fully develop. The local hospital did not have the capacity to treat Demao, and the doctor advised his parents there was nothing that could be done. His parents, not willing to give up on their child, continued to research his medical condition and discovered that others with the same affliction had received successful medical treatments in Shanghai. Not able to afford proper medical transportation, his father held him on his lap for a 30-hour train ride to Shanghai. When they arrived at the hospital, Demao was dehydrated and anemic. His doctor immediately operated to create a colostomy in the hope of increasing his weight to 12-13 pounds, which would be an operable weight. The original surgery was estimated at RMB200,000 (USD32,000).



Demao at 3-month old



March 2015: Prior to one of his many surgeries

In January 2014, with donations from several charities including A Life A Time Foundation, Demao had esophagus repair surgery. After the surgery, he suffered infections and relapses of his condition. It has been two years since his diagnosis, and he is still tormented by this condition at age 2. Since August 2013, Demao has had over 10 surgeries, both big and small, but his ordeal is far from over. His doctor informed Demao's parents that more surgeries will be needed after their child takes some time to recover. Near term medical expenses are expected to be about RMB400,000 (USD64,000). This little boy, who has spent most of his life in hospitals, still needs your help.

Xin

Gender: Female

Disease/Illness: Congenital Heart Disease

Date of Birth: November 2008

Contribution from A Life A Time: \$1,615.00

Story link: <http://www.alifeatime.org/cn/children/story.aspx?id=883>

Xin is the older of twin sisters from Sichuan province. Her health was never as good as her sister's. She often caught colds, which further developed into pneumonia. When she was sick, her lips would turn black. Because the family was poor they did not follow up with doctors regarding her symptoms, and she never had her condition examined. As she grew older, her illness became more severe. At one point, she could not even walk on her own. In March 2015, she underwent a Doppler ultrasound and she was diagnosed with congenital heart disease. However, with meager earnings of less than RMB10,000 (USD1,563) per year for the whole family, they could not afford the necessary surgery to treat Xin.



Xin: Prior to her surgery



July 2015: Post-surgery

In May 2015, with the help of a Chinese charity, Xin had her cardiac surgery at Chengdu Military General Hospital. However, because her lung did not function properly, the post-surgery recovery was not as good as expected. As a result, her medical expenses significantly exceeded the original estimate. By June, her hospital charge totaled RMB120,000 (USD18,750), which had not been fully paid. On June 12, with her

condition having stabilized, she was finally discharged from the hospital. A Life A Time Foundation and Chinese Agape Foundation together provided RMB17,000 (USD2,737) to help with her medical expenses.

Zishan

Gender: Female

Disease/Illness: Congenital Esophageal Stenosis

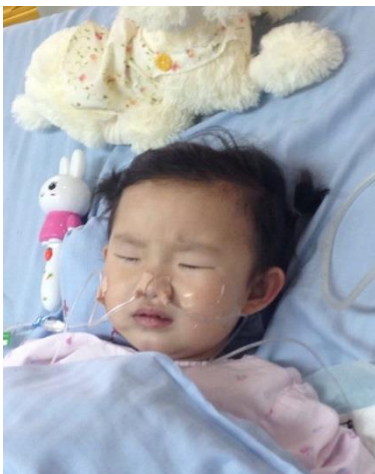Date of Birth: May 2011

Contribution from A Life A Time: \$ 1,617.17

Story link: <http://www.alifeatime.org/cn/children/story.aspx?id=869>

Zishan was diagnosed with congenital esophageal hiatal hernia when she was born. She was later transferred to various local hospitals but was not treated due to limited resources at those hospitals. In 2013, she underwent a hernia repair surgery at Hunan Children's Hospital, but her condition did not improve. At her last checkup at the Hunan Children's Hospital, she was diagnosed with esophageal stricture and reflux esophagitis in addition to congenital esophageal hiatal hernia. Because of limited resources, Zishan was referred to Children's Hospital of Fudan University in Shanghai. At the end of 2014, she had another surgical hernia repair. The surgery also included an esophageal dilation to stretch the narrowed area of esophagus. The procedure was successful and she underwent another esophageal dilation in February 2015. Unexpectedly, an esophageal rupture occurred and required emergency medical care for Zishan. Her condition eventually was stabilized and she was released from the hospital in April.

Zishan's condition requires an esophageal dilation every month, which she has gone through three times since May, with the first one performed three week after she was released from the hospital. A Life A Time Foundation supported her dilation procedures in June and July.



April 2015: At the hospital



June 2015: Post her fourth esophageal dilation.

Zishan is from a family with nine members. Because of her condition, the family has spent all of their savings (approx. RMB100,000 or USD15,576) since she was born and is also in debt for over RMB200,000 (USD31,152). Zishan's father was a truck driver but is no longer able to work in order to take care of his

daughter. The family currently has no income, and relies on donations and financial aid from various nonprofit organizations to pay for the child's medical expenses.

Ri

Gender: Male

Disease/Illness: Burn

Date of Birth: August 2007

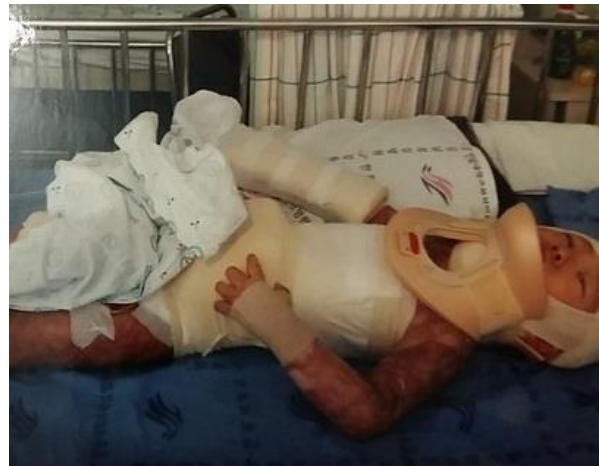Contribution from A Life A Time: \$808.58

Story link: <http://www.alifeatime.org/cn/children/story.aspx?id=880>

On February 2, 2011, three-year-old Ri fell into a pot of boiled scrap and was severely burned. After the burn areas were treated and healed, hypertrophic scarring formed throughout the burned areas, resulting in joint adhesions and contracture that made him unable to stand or walk. Over the next four years, Ri went through over 20 skin grafts. Some of the injured areas improved, but he was still not able to squat or get dressed himself. His doctor suggested that more skin grafting would be needed as he grows.



Ri: Before the incident



Ri: Being treated after the incident

Ri's story was reported when the incident first happened and many people extended their support through donations or other means. The child's condition improved in the past four years. However, even with all the donations and other help received, Ri's medical care has left the family with over RMB400,000 (USD62,500) in debt, and they can no longer afford further treatments. In July 2015, with help from a charity in China, Ri was transferred to Beijing to continue his treatments and recovery. A Life A Time Foundation sent RMB5,000 to support a part of the medical expenses.

We would like to ask for your continued support in the future by visiting our website: <http://www.alifeatime.org> or our fundraising platform on GlobalGiving.

Please spread the word of our fundraising efforts to your family members, friends and colleagues.

Thank you again, and together let's help as many children as possible and allow them to experience love and be treated with dignity and care!

Sincerely yours,

A Life A Time Foundation